

Orthodontics-Surgery-Prosthodontics Teamwork

Ortodonti-Cerrahi-Protez İşbirliği

Berza ŞEN YILMAZ¹, Nazan KÜÇÜKKELEŞ², Banu ÇAKIRER BAKKALBAŞI³, Mehmet Zeki GÜZEL²

¹Department of Ortodontics, Bezmalem Vakıf University School of Dentistry, İstanbul, Turkey

²Private Practice, İstanbul, Turkey

³Department of Ortodontics, Marmara University School of Dentistry, İstanbul, Turkey

ABSTRACT

The consciousness and expectations of orthodontic patients have evolved with the increasing esthetic requirements of the society. Therefore, interdisciplinary intervention is crucial to achieve better results. A 19-year-old female patient presenting with posterior cross-bite, anterior open-bite, and laterognathia applied for treatment with the chief complaint of her unpleasant general facial appearance. The treatment plan included surgically assisted rapid maxillary expansion (SARME), double jaw surgery, and prosthetic restoration of the anterior teeth. The corticotomy was performed under general anesthesia and was followed by SARME. After leveling, stainless steel wires were placed, and Class II elastics were used for the decompensation of incisor teeth inclination. During surgery, maxillary advancement and mandibular set back were performed. The laterognathia was corrected with the rotation of the maxilla and bone removal from the hypertrophic side of the mandibular corpus. Following the removal of the orthodontic appliances, home bleaching and prosthodontic rehabilitations were performed. The patient ended up with the ideal facial criteria and an esthetic smile after 18 months of treatment.

Keywords: Double jaw surgery, facial asymmetry, interdisciplinary treatment

ÖZ

Artan estetik gereksinimler ortodonti hastalarının tedavi bilinçlerinin gelişmesine ve beklentilerinin artmasına sebep olmuştur. İnterdisipliner çalışmalar bağlamda önem kazanmaktadır. Bu vaka raporunun amacı 19 yaşında, maloklüzyon ve laterognatiden şikayet eden bir hastanın ortodontik, cerrahi ve protetik yaklaşımla tedavisini örneklemektir. Üst çene darlığına bağlı arka çapraz kapanış, ön açık kapanış gibi düzensizliklerin yanı sıra iskeletsel laterognati teşhis edilmiştir. Tedavi planı SARME ve çift çene ortognatik cerrahi öncesi dekompanasyon ve bunu takiben protetik rehabilitasyonu içermektedir. Kortikotomi genel anestezi altında yapılmış, ardından hızlı üst çene genişletmesi uygulanmıştır. Seviyeleme sonrası çelik tellere geçilmiş ve Sınıf II lastiklerle dekompanasyon sağlanmıştır. Cerrahi sırasında maksiller ilerletilmiş, mandibulanın geri alınmıştır. Laterognati maksillanın rotasyonu ve mandibular korpusun hipertrofik kısmından kemik eksiltilmesi ile düzeltilmiştir. Ortodontik tedaviden sonra ev tipi beyazlatma işlemi uygulanmıştır. Bunu takiben hastanın ön dişlerine lamina veneer ve çekim boşluğuna köprü uygulaması yapılarak hastanın estetik gereksinimi karşılanmış ve fonksiyonu düzeltilmiştir. Hasta 18 aylık tedavi sonucunda ideal yüz kriterlerine ve estetik bir gülüşe kavuşmuştur.

Anahtar Kelimeler: Çift çene cerrahi, fasyal asimetri, interdisipliner tedavi

Introduction

It should be noted that the role of interdisciplinary intervention is crucial while treating a patient who does not only need dental correction but also a total face reconstruction (1).

Facial asymmetry is defined as a difference in the size or shape of the sides of the face (2). Dental asymmetries and functional deviations can be treated orthodontically in young patients, whereas surgical interventions are needed at later ages.

The following case report will illustrate the treatment of an adult patient presenting Class III skeletal pattern with facial asymmetry by orthodontic, surgical, and prosthodontic teamwork.

Case Report

A 19-year-old female patient presented to our clinic with the chief complaints of facial asymmetry and unesthetic smile. Clinical examination revealed Class III skeletal malocclusion characteristics: malar deficiency, deep nasolabial sulcus, and inferior

Address for Correspondence/Yazışma Adresi: Berza ŞEN YILMAZ; Bezmalem Vakıf Üniversitesi, Diş Hekimliği Fakültesi Ortodonti Anabilim Dalı, İstanbul, Türkiye E-mail: berzasen@hotmail.com

©Copyright 2016 by Bezmalem Vakıf Üniversitesi - Available online at www.bezmalemscience.org

©Telif Hakkı 2016 Bezmalem Vakıf Üniversitesi - Makale metnine www.bezmalemscience.org web sayfasından ulaşılabilir.

Received / Geliş Tarihi : 11.11.2015

Accepted / Kabul Tarihi: 04.01.2016



Figure 1. Initial extraoral images

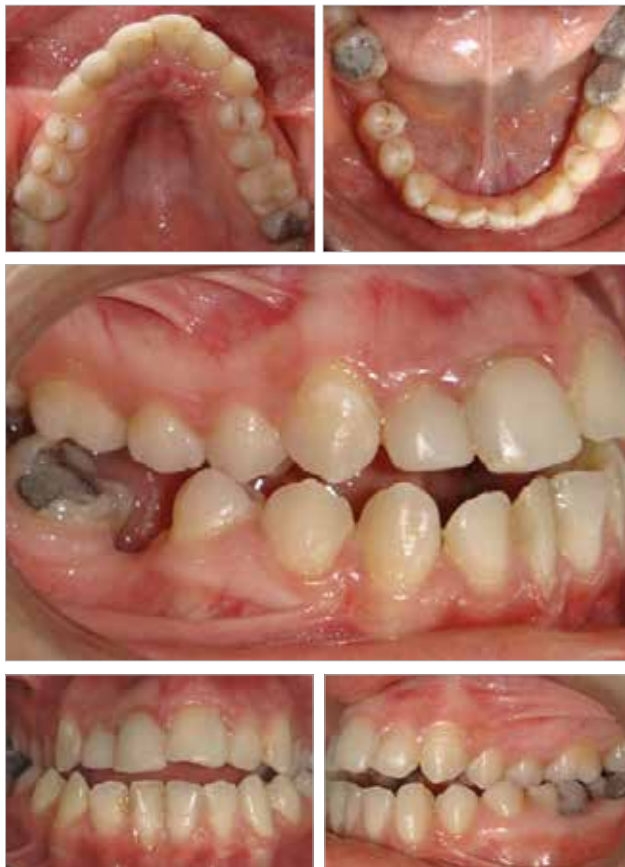

Figure 2. Initial intraoral images

sclera exposure at rest. The chin was deviated to the right, and the corpus had an asymmetrical shape. She also showed soft tissue asymmetry during smiling because of the right depressor labii inferioris muscle being less active than the left (Figure 1). She had lower anterior crowding, anterior open bite, and posterior cross-bite. Esthetically unsatisfactory old resin restorations were present on her upper anterior teeth (Figure 2). The upper and lower dental midlines were both shifted 1.5 mm to the right.

The cephalometric measurements supporting the clinical examination findings revealed a high angle skeletal pattern and Class III skeletal relationship related to a retrognathic maxilla (Table 1). Evaluation of the anteroposterior cephalometric radiograph revealed that the facial asymmetry was due to the

Table 1. The patient's cephalometric measurements

	Pretreatment	Before Surgery	After Surgery
SNA	70°	72°	78°
SNB	75°	75°	73°
ANB	-5°	-2°	3°
Wit's	-13mm	-15mm	2mm
N A	-9mm	-7,5mm	-3mm
Zinner angles	404°	403°	401°
FMA	32°	30°	28°
Jarabak	61%	61%	62%
UI/SN	112°	104°	101°
IMPA	85°	88°	88°
UI/Occlusal PL	53°	57°	57°
LI/Occlusal PL	68°	67°	67°

SNA: sella-nasion-A point angle; SNB: sella-nasion-B point angle; ANB: A point-nasion-B point angle; N \perp A: nasion perpendicular to A point distance; Zinner angles: sum of the gonial, articular and saddle angles; FMA: Frankfort-Mandibular plane angle UI/SN: upper incisor to sella-nasion plane distance; IMPA: lower incisor to mandibular plane angle; UI/Occlusal PL: upper incisor to occlusal plane angle; LI/Occlusal PL: lower incisor to occlusal plane angle

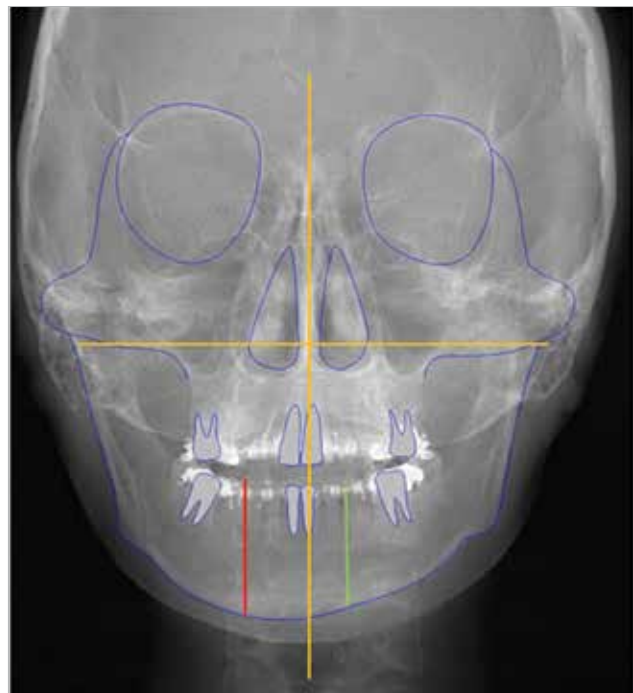


Figure 3. Posteroanterior X-ray showing the mandibular asymmetry

skeletal shift of both jaws along with mandibular corpus morphologic difference between the right and left sides (Figure 3).

The case was discussed among a prosthodontist, orthodontist, and plastic surgeon. Other treatment alternatives that comprised prosthetic restorations alone were also discussed. A maxillary complete fixed prosthesis would have restored her occlusion; however, the contribution to facial esthetics would

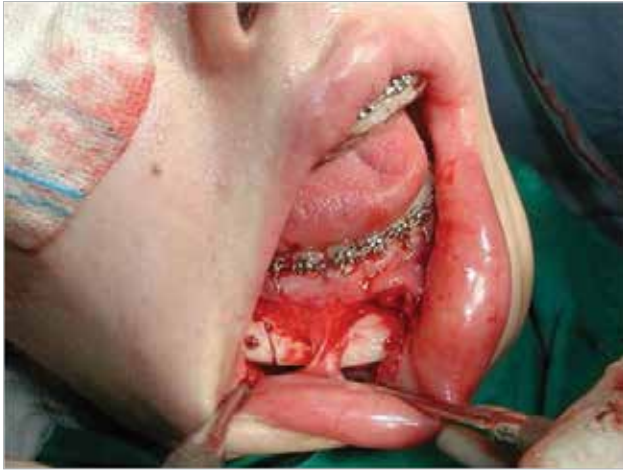

Figure 4. Intraoral images after the orthodontic treatment

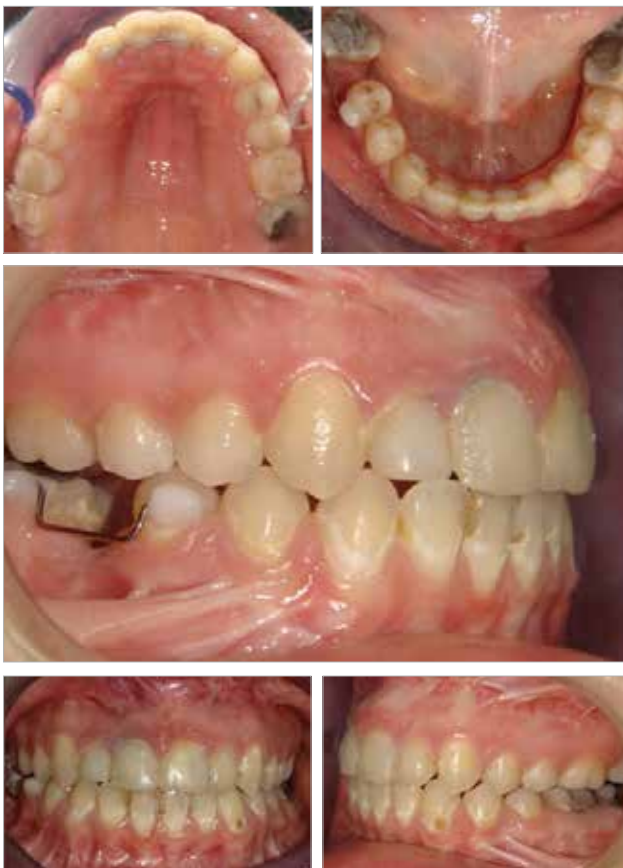

Figure 5. Bone removal from the hypertrophic side of the mandible

have been limited, and the asymmetry would not have been corrected. Further, considering her age and the health status of her teeth and to be able to establish an ideal emergence profile, the esthetic restoration of the anterior teeth was postponed to the end of the orthodontic and surgical interventions. After the oral maintenance and hygiene instructions, the patient was referred to the orthodontics clinic. The ortho-

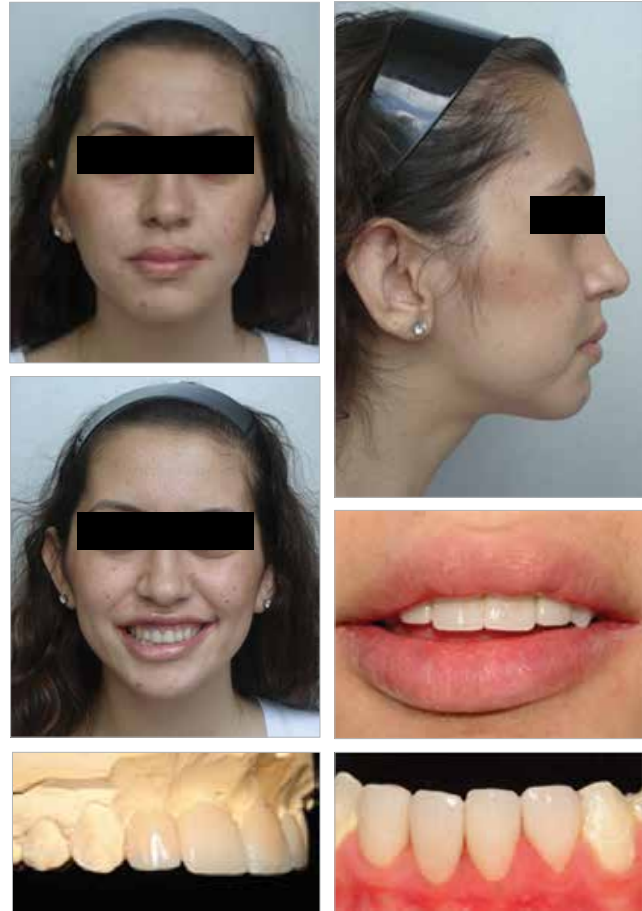

Figure 6. Extraoral images after debonding and laminate restorations for the anterior teeth

odontic treatment plan included the expansion of the maxilla by surgically assisted rapid maxillary expansion (SARME) and decompensation therapy to correct the incisor inclinations before double jaw surgery and uprighting the mesially inclined lower right first molar. The treatment plan was explained to the patient and written informed consent was signed.

The treatment plan was explained to the patient, and written informed consent was obtained. Corticotomy was performed under general anesthesia. Following the 7-day latency period of the surgery, the maxilla was expanded by turning the expansion screw twice a day for 10 days. After a 3-month retention period with the Hyrax appliance in the mouth, a Quad-Helix appliance was bonded to correct the dental arch shape and the buccolingual inclination of the posterior teeth. At the end of the leveling stage, Class II elastics were used to decamouflage the incisor inclinations.

The surgery plan included 4 mm of maxillary advancement with a 1-mm rotation to the left. Maxilla was impacted 1 mm in the anterior and 2 mm in the posterior. Mandibular rotation and set-back was performed to compensate the maxillary movement. The corpus asymmetry was remedied by bone removal from the hypertrophic side during the double jaw surgery to mirror the left corpus shape (Figure 4). Heal-

ing period was uneventful, with improved facial esthetics; the maxillary advancement augmented the upper lip support and eliminated the deep nasolabial folds.

After the orthodontic treatment, the patient was referred to the prosthodontics department and the prosthodontic treatment phase was initiated (Figures 5). The gingival margins were leveled by gingivectomy using electrosurgery. Home bleaching was performed using 16% carbamide peroxide. The patient was advised to wear the custom made trays with the bleaching agent for 10 consecutive nights for at least 7 h per night. The patient had old resin restorations on the upper anterior teeth, and she developed white spot lesions because of the orthodontic treatment. The upper and lower four anterior teeth were restored by porcelain laminate veneers (Figure 6). The Class V cavities on the canines were restored with composite resin fillings. Because of economic conditions, patient opted for a fixed bridge instead of a dental implant for the lower right first molar's extraction space.

Class I skeletal and dental relationships with acceptable facial proportions and a more esthetic smile were achieved after 18 months of treatment (Table 1).

Discussion

It is important to diagnose the components causing asymmetry to obtain satisfactory treatment results (3-6). The analysis of posteroanterior cephalometric radiographs determines if the asymmetry is related to the maxilla, mandible, or both and if the anomaly is also associated with dental compensations (7). In the case presented above, the asymmetry was related to both jaws, resulting in midline shift and chin deviation.

Furthermore, the patient had a constricted maxilla with bilateral crossbite. As reported in the literature, the etiology of a crossbite is not always evident. According to Haraguchi et al. (8), posterior crossbite can be a consequence of a narrow maxilla, or it may simply be a result of mandibular deviation. In the present case, the maxilla was skeletally constricted and the dental arch was narrow. Although the posterior crossbite was treated with SARME, the arch shape was corrected with dental expansion.

Orthognathic surgery is required to restore the esthetic and functional balance in patients with moderate-to-severe skeletal discrepancies (9). This patient had Class III skeletal pattern with asymmetry, and she was expecting optimal treatment results. The patient accepted the surgical interventions; thereby the following prosthetic rehabilitation fulfilled all her requirements.

Conclusion

Satisfactory treatment results can be obtained with a multidisciplinary treatment approach based on realistic treatment objectives considering each patient's characteristics and expectations.

Informed Consent: Written informed consent was obtained from patients.

Peer-review: Externally peer-reviewed.

Author Contributions: Concept - B.S.Y., N.K., B.C.B.; Design - B.S.Y., N.K., B.C.B.; Supervision - N.K., B.C.B.; Funding - B.S.Y.; Materials - B.S.Y.; Data Collection and/or Processing - B.S.Y., M.Z.G.; Analysis and/or Interpretation - B.S.Y., N.K., B.C.B.; Literature Review - B.S.Y.; Writing - B.S.Y.; Critical Review - N.K., B.C.B., M.Z.G.

Acknowledgement: This case report was presented at the 111th Annual Congress of American Association of Orthodontists, 2011, with the support of Marmara University Scientific Research Projects Commission (Project number SAG-D-070211-0003).

Conflict of Interest: No conflict of interest was declared by the authors.

Financial Disclosure: The authors declared that this study has received no financial support.

Hasta Onamı: Yazılı hasta onamı bu çalışmaya katılan hastalardan alınmıştır.

Hakem Değerlendirmesi: Dış bağımsız.

Yazar Katkıları: Fikir - B.S.Y., N.K., B.C.B.; Tasarım - B.S.Y., N.K., B.C.B.; Denetleme - N.K., B.C.B.; Kaynaklar - B.S.Y.; Malzemeler - B.S.Y.; Veri Toplanması ve/veya İşlemesi - B.S.Y., M.Z.G.; Analiz ve/veya Yorum - B.S.Y., N.K., B.C.B.; Literatür Taraması - B.S.Y.; Yazıyı Yazan - B.S.Y.; Eleştirel İnceleme - N.K., B.C.B., M.Z.G.

Teşekkür: Bu olgu sunumu 111. Amerikan Ortodontistler Derneği Yıllık Kongresi'nde (2011), Marmara Üniversitesi Bilimsel Araştırma Projeleri Komisyonu desteğiyle sunulmuştur (Proje numarası: SAG-D-070211-0003).

Çıkar Çatışması: Yazarlar çıkar çatışması bildirmemişlerdir.

Finansal Destek: Yazarlar bu çalışma için finansal destek almadığını belirtmiştir.

References

1. Glineur R, Balon-Perin A. A multidisciplinary approach to orthognathic surgery. *Rev Belge Med Dent* 2002; 57: 24-31.
2. Bishara SE, Burkey PS, Kharouf JG. Dental and facial asymmetries: a review. *Angle Orthod* 1994; 64: 89-98.
3. Decker JD. Asymmetric mandibular prognathism: a 30-year retrospective case report. *Am J Orthod Dentofacial Orthop* 2006; 129: 436-43. [\[CrossRef\]](#)
4. Hayashi K, Muguruma T, Hamaya M, Mizoguchi I. Morphologic characteristics of the dentition and palate in cases of skeletal asymmetry. *Angle Orthod* 2004; 74: 26-30.
5. Ko EW, Huang CS, Chen YR. Characteristics and corrective outcome of face asymmetry by orthognathic surgery. *J Oral Maxillofac Surg* 2009; 67: 2201-9. [\[CrossRef\]](#)
6. Sekiya T, Nakamura Y, Oikawa T, Ishii H, Hirashita A, Seto K. Elimination of transverse dental compensation is critical for treatment of patients with severe facial asymmetry. *Am J Orthod Dentofacial Orthop* 2010; 137: 552-62. [\[CrossRef\]](#)
7. Bergamo AZ, Andruccioli MC, Romano FL, Ferreira JT, Matsumoto MA. Orthodontic-surgical treatment of Class III malocclusion with mandibular asymmetry. *Braz Dent J* 2011; 22: 151-6. [\[CrossRef\]](#)
8. Haraguchi S, Takada K, Yasuda Y. Facial asymmetry in subjects with skeletal Class III deformity. *Angle Orthod* 2002; 72: 28-35.
9. Pektaş ZÖ, Kircelli BH. Interdisciplinary management of an adult patient with a class III malocclusion. *J Prosthet Dent* 2014; 112: 9-13. [\[CrossRef\]](#)