

# Isolated Traumatic Facial Palsy Based on Pinprick to the Tympanic Membrane

## Timpanik Membrana Şiş Batmasına Bağlı İzole Periferik Fasyal Paralizi

Selahattin TUĞRUL, Erol ŞENTÜRK, Seda SEZEN GÖKTAŞ, Sabri Baki EREN, Orhan ÖZTÜREN  
Department of Otorhinolaryngology, Bezmialem Vakıf University Faculty of Medicine, Istanbul, Turkey

### ABSTRACT

Transtympanic penetrating trauma is one of the reasons of rarely seen peripheral facial paralysis. In this case, we observed the traumatic facial paralysis which was formed by the facial canal damage of the dehiscence tympanic segment of the facial nerve as a result of a knitting needle penetrating the tympanic membrane, which was not previously studied in the literature.

**Keywords:** Peripheral facial paralysis, transtympanic penetrating trauma, facial canal dehiscence

### ÖZET

Transtimpanik penetran travma, periferik fasyal paralizilerin nadir görülen nedenleri arasındadır. Literatürde daha önce benzerine rastlamadığımız bu olgumuzda, fasyal kanal timpanik segment dehissansına bağlı olarak timpanik membrana örgü şişi batması sonrası periferik fasyal paraliziye rastladık.

**Anahtar Sözcükler:** Periferik fasyal paralizi, transtimpanik penetran travma, fasyal kanal dehissansı

### Introduction

Trauma-based facial paralysis is the second cause of peripheral facial paralysis after Bell's palsy. The frequency of occurrence of Bell's paralysis is 51%, trauma 22%, herpes zoster oticus 7%, tumors 6%, and infection 4% (1).

In the middle 2/3<sup>rd</sup> of the facial canal, the rate of dehiscence is between 41% and 74%. In a study in which the temporal bone was reviewed, the rate of dehiscence was 55%; 91% out of these was in the tympanic segment and 9% in the mastoid segment. Facial canal dehiscence for 83% of the ones occurring in the tympanic segment was located adjacent to the oval window, and the facial nerve was protruded from the canal in 26% of those (2). Therefore, this causes the tympanic segment to become more susceptible to trauma.

The reason for the most frequent occurrence of facial paralysis is the blunt trauma of the temporal bone, followed by penetrating traumas. Penetrating traumas are generally associated with hearing loss because of the dislocation of the middle ear ossicles. We presented a case with facial paralysis as a result of penetrating trauma, but with the hearing preserved.

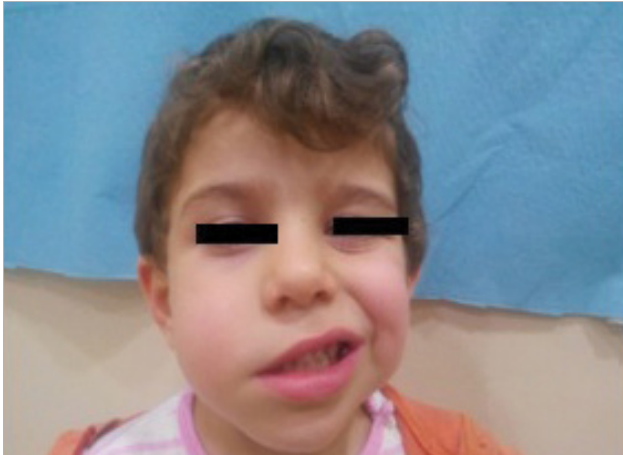### Case Presentation

A 3-year-old girl presented to our clinic with a complaint of being unable to close her right eyelid and displacement of the mouth because of a sharp object (thin knitting needle) that penetrated the right external auditory canal a day prior to the hospital visit. According to information obtained from the patient's family, her complaints had realised morning after the trauma (approximately 6 h). No known disease or drug use history for the patient was present. No experience of facial paralysis history was present. The examinations revealed grade 4 peripheral paralysis on the right side according to the House-Brackmann staging scale (Figure 1). In the otoscopic examination, the right external auditory canal showed a normal appearance. The otoscopic examination also revealed a hyperemic and bleeding area, approximately 3 mm in diameter, in the right tympanic membrane (posterosuperior quadrant), and a pinpoint perforation was also observed at the tympanic membrane (Figure 2). Other otorhinolaryngology examinations were normal. As a result of temporal computed

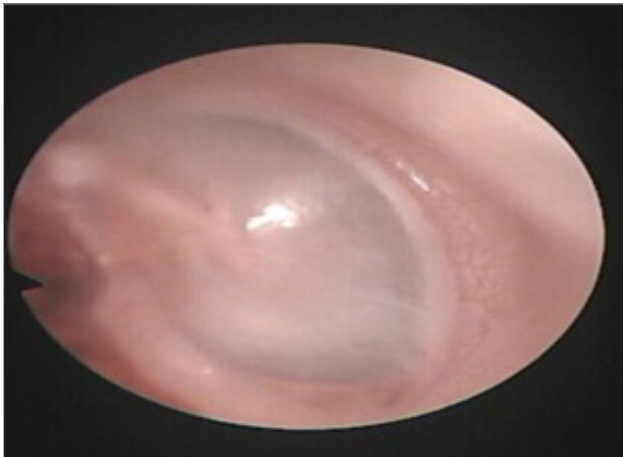
**Address for Correspondence / Yazışma Adresi:** Seda Sezen Göktas; Department of Otorhinolaryngology, Bezmialem Vakıf University Faculty of Medicine, Istanbul, Turkey Phone: +90 546 438 24 11 E-mail: sedasezengoktas@gmail.com

©Copyright 2015 by Bezmialem Vakıf University - Available online at [www.bezmialemscience.org](http://www.bezmialemscience.org)

©Telif Hakkı 2015 Bezmialem Vakıf Üniversitesi - Makale metnine [www.bezmialemscience.org](http://www.bezmialemscience.org) web sayfasından ulaşılabilir.



**Figure 1.** Grade 4 right peripheral paralysis according to the House–Brackmann staging scale



**Figure 2.** Pinpoint perforation was seen at the tympanic membrane

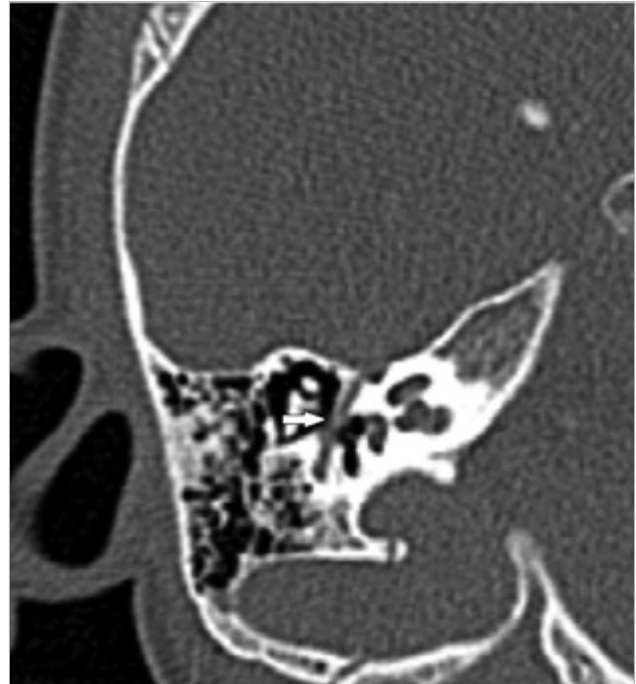tomography (CT), facial dehiscence was identified at the right ear tympanic segment, and no dislocation was present in the ossicular chain (Figure 3) and the normal left side (Figure 4). The auditory brain stem response (ABR) test showed that the hearing of the patient was normal.

Parenteral administration of methylprednisolone (1 mg/kg/day) was started. On the 3<sup>rd</sup> day, the methylprednisolone dose was reduced to 0.5 mg/kg. On the 6<sup>th</sup> day of her treatment, because the facial paralysis was decreased to House–Brackmann grade 3, the methylprednisolone dose was reduced to half and her treatment continued via the oral route. Her facial paralysis was completely healed on the 20<sup>th</sup> day of treatment.

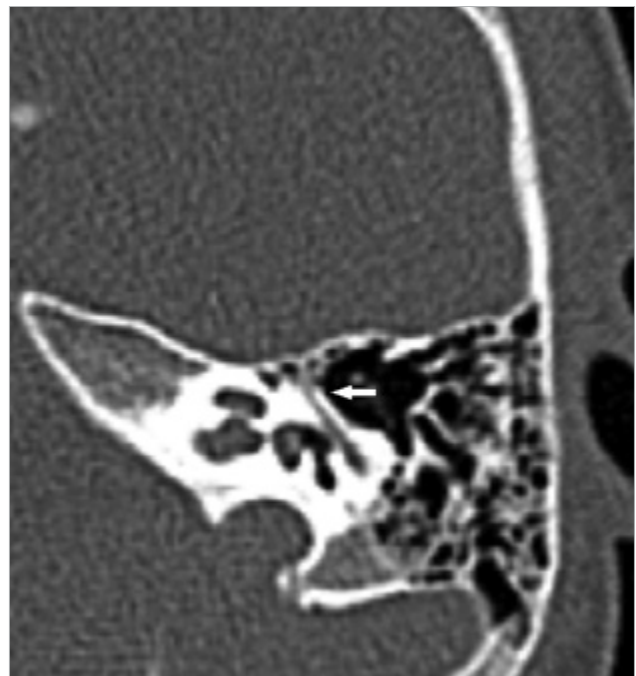## Discussion

Facial paralysis is the most seen cranial nerve paralysis in clinics. The most frequent reason for traumatic damage of the facial nerve is the temporal bone fracture. The other reasons are penetrating traumas and iatrogenic injuries.

Firearm injuries are the most common among penetrating injuries. Firearm injuries are serious injuries, often caused by dural rupture, cerebrospinal fluid (CSF) rhinorrhea, damage in the otic capsule, and vascular damages.



**Figure 3.** Facial dehiscence at the right ear tympanic segment



**Figure 4.** The normal left side

Penetrating trauma through the external auditory canal is extremely rare. The complications of the penetrating traumas from the external auditory canal are tympanic membrane perforation, hearing loss and tinnitus, vertigo, otorrhea, ossicular chain damage, cholesteatoma development in late period, perilymph fistula, and peripheral facial paralysis. Because of each three ossicular chain, oval window, and localization of the facial nerve, there are more risks that the tympanic membrane may be exposed to penetrating trauma from the posterosuperior quadrant.

Chronic tympanic membrane perforation and chronic otitis is frequently observed as a result of transtympanic spark splash. However, there are two cases present in the literature with transtympanic spark splash: one of them developed temporal facial paralyses and the other became deaf and developed facial paralysis as a result of cochlear injury (3).

Moseme et al. (4) presented a case with hearing loss and facial paralysis, which developed as a result of penetrating trauma by a foreign body penetrating the external auditory canal as a result of a bicycle accident.

In the study of Lasak et al. (5) conducted on 44 patients having transtympanic middle ear penetrating trauma, the patients were divided into the early applicers to the hospital (in 1 month) and late applicers (after 1 month). Facial paralysis was identified only in two of (9%) the late applicers. It was observed that cholesteatoma that developed in one of them had infiltrated the fallopian canal, and chorda tympani damage was observed in the other patient.

## Conclusion

Transtympanic penetrating trauma is one of the reasons of rarely seen peripheral facial paralysis. In this case, we observed the traumatic facial paralysis which was formed by the facial canal damage of the dehiscent tympanic segment of the facial nerve as a result of a knitting needle penetrating the tympanic membrane. Because of facial canal dehiscence or differences in the course of the facial nerve, transtympanic penetrating traumas should be considered among the differential diagnoses of peripheral facial paralysis.

**Informed Consent:** Written informed consent was obtained from patient's parents.

**Peer-review:** Externally peer-reviewed.

**Author Contributions:** Concept - S.T., S.B.E.; Design - E.Ş., S.S.G.; Supervision - F.T., S.B.E.; Funding - E.Ş., S.S.G.; Materials - E.Ş.; Data Collection and/or Processing - S.S.G., S.B.E.; Analysis and/or Interpretation - S.T.; Literature Review - S.S.G., E.Ş.; Writer - S.S.G., E.Ş.; Critical Review - S.B.E., S.T.

**Conflict of Interest:** The authors declared no conflict of interest.

**Financial Disclosure:** The authors declared that this study has received no financial support.

**Hasta Onamı:** Yazılı hasta onamı bu çalışmaya katılan hastanın ailesinden alınmıştır.

**Hakem Değerlendirmesi:** Dış bağımsız.

**Yazar Katkıları:** Fikir - S.T., S.B.E.; Tasarım - E.Ş., S.S.G.; Denetleme - F.T., S.B.E.; Kaynaklar - E.Ş., S.S.G.; Malzemeler - E.Ş.; Veri toplanması ve/veya işlemesi - S.S.G., S.B.E.; Analiz ve/veya yorum - S.T.; Literatür taraması - S.S.G., E.Ş.; Yazıyı yazan - S.S.G., E.Ş.; Eleştirel inceleme - S.B.E., S.T.

**Çıkar Çatışması:** Yazarlar çıkar çatışması bildirmemişlerdir.

**Finansal Destek:** Yazarlar bu çalışma için finansal destek almadıklarını beyan etmişlerdir.

## References

1. Aggarwal SK, Gupta AK, Modi M, Gupta R, Marwaha N. Safety Profile of Bone Marrow Mononuclear Stem Cells in the Rehabilitation of Patients with Posttraumatic Facial Nerve Paralysis - A Novel Modality (Phase One Trial). *J Neurol Surg B Skull Base* 2012; 73: 245-52. [\[CrossRef\]](#)
2. Baxter A. Dehiscence of the fallopian canal. An anatomical study. *J Laryngol Otol* 1971; 85: 587-94. [\[CrossRef\]](#)
3. Panosian MS, Wayman JW, Dutcher PO Jr. Facial nerve paralysis from slag injury to the ear. *Arch Otolaryngol Head Neck Surg* 1993; 119: 548-50. [\[CrossRef\]](#)
4. Moseme TM, Andronikou S, Theron S. Transtympanic facial nerve palsy after mountain bike accident. *J Trauma* 2011; 71: E101. [\[CrossRef\]](#)
5. Lasak JM, Van Ess M, Kryzer TC, Cummings RJ. Middle ear injury through the external auditory canal: a review of 44 cases. *Ear Nose Throat J* 2006; 85: 722, 724-8.