



Pseudohypoparathyroidism Type Ia with Normocalcemia

Normokalsemik Seyreden Psödohipoparatiroidizm Tip Ia

Esra KUTLU¹, İlker Tolga ÖZGEN¹, Yaşar CESUR², Gözde YEŞİL³

¹Bezmialem Vakıf University Faculty of Medicine, Department of Child Endocrinology, İstanbul, Turkey

²Bezmialem Vakıf University Faculty of Medicine, Department of Child Endocrinology and Metabolism, İstanbul, Turkey

³Bezmialem Vakıf University Faculty of Medicine, Department of Medical Genetics, İstanbul, Turkey

ABSTRACT

Pseudohypoparathyroidism (PHP) is a heterogeneous group of disorder with parathormone target organ resistance, characterized by hypocalcemia, hyperphosphatemia and high blood parathormone (PTH). Typical phenotypic symptoms and additional hormonal resistance can be observed in type Ia, which is also known as Albright hereditary osteodystrophy. Our patient was an eight-year and nine-month old girl with typical Albright's hereditary osteodystrophy phenotype including short stature, obesity, round face, low nasal bridge, shortened metacarpals, and mild mental retardation. In her biochemical examination, high PTH level and hypothyroidism is detected in spite of normal calcium and phosphor levels. As a result of clinic and laboratory tests, the findings were consistent with PHP type Ia with normocalcemia. In her guanine nucleotide binding protein (G protein), alpha stimulating activity polypeptide 1 (*GNAS*) gene serial analysis, C-308T>C (p1103T) transformation was detected, which was previously reported in a PHP type Ia patient. In this report, we've aimed to emphasize the fact that calcium and phosphor level in the blood of the patient with PHP type Ia can be measured normal.

Keywords: Pseudohypoparathyroidism, albright hereditary osteodystrophy, normocalcemia, short stature

ÖZ

Psödohipoparatiroidizm (PHP); parathormon hedef organ direnci olan, hipokalsemi, hiperfosfatemi ve kan parathormon (PTH) yüksekliği ile karakterize heterojen bir hastalık grubudur. Albright'ın herediter osteodistrofisi olarak da adlandırılan tip Ia'da tipik fenotipik bulgular ve ek hormon dirençleri de görülebilmektedir. Kısa boy, obezite, yuvarlak yüz, basık burun kökü, kısa metakarpalar ve hafif mental retardasyon gibi Albright'ın herediter osteodistrofisinin tipik bulguları olan kız hastamız 8 yıl 9 aylık idi. Biokimyasal tetkiklerinde normal kalsiyum ve fosfor düzeylerine rağmen yükselmiş PTH düzeyi ve hipotiroidizm saptandı. Hastanın klinik ve laboratuvar bulguları normokalsemik seyreden PHP tip Ia ile uyumlu bulundu. Guanin bağlayıcı protein (G protein), alfa subunit 1 (*GNAS*) geni dizi analizi sonucunda daha önce PHP tip Ia'lı olguda bildirilen C-308T>C (p1103T) değişimi saptandı. Burada PHP tip Ia'da kan kalsiyum ve fosfor düzeylerinin normal saptanabileceğini vurgulamak istedik.

Anahtar Sözcükler: Psödohipoparatiroidizm, albright herediter osteodistrofisi, normokalsemi, kısa boy

Introduction

Pseudohypoparathyroidism (PHP) is an autosomal dominant disorder, which is related with parathormone target organ resistance resulting from mutations in guanine nucleotide binding protein

(G protein) and alpha stimulating activity polypeptide 1 (*GNAS*) genes. It is characterized by hypocalcemia, hyperphosphatemia and elevated PTH levels (1). The disorder occurs as a result of maternal transmission of the mutation. As Gs alpha protein activity is necessary for other hormones such as thyroid-stimulating

Address for Correspondence/Yazışma Adresi: Esra KUTLU, Bezmialem Vakıf University Faculty of Medicine, Department of Child Endocrinology, İstanbul, Turkey
Phone: +90 505 520 3411 **E-mail:** esrakutlu07@gmail.com **ORCID ID:** orcid.org/0000-0002-4554-1631

Received/Geliş Tarihi: 15.12.2017
Accepted/Kabul Tarihi: 29.03.2018

Cite this article as: Kutlu E, Özgen İT, Cesur Y, Yeşil G. Pseudohypoparathyroidism Type Ia with Normocalcemia. Bezmialem Science 2019;7(2):170-3.

©Copyright 2019 by the Bezmialem Vakıf University
Bezmialem Science published by Galenos Publishing House.

hormone (TSH), luteinizing hormone (LH), follicle-stimulating hormone (FSH), and gonadotropin-releasing hormone (GnRH), growth hormone-releasing hormone (GHRH), resistance against these hormones may also exist (2-6). Characteristic phenotypic features such as short stature, obesity, round face, low nasal bridge, shortened metacarpals, shortness and thickness in distal phalanges, subcutaneous calcifications, polyostotic fibrous dysplasia, developmental delay, and besides, mental retardation can be observed in these patients (1,7). This phenotype is named as "Albright hereditary osteodystrophy" (AHO).

Some cases with PHP type Ia are present with heterogeneity in terms of their phenotypical and biochemical characteristics (8-11). In this paper, an eight-year and nine-month-old female with normocalcemic PHP type Ia is reported.

Case Report

Eight-year and nine-month-old female patient was admitted to the hospital with the complaint of having short stature with a height of 117.2 cm (<3p, -2.5 SDS) and weight of 28.9 kg (50-75p, 0.124 SDS). She was term born, birth weight was 3100 gr (25-50 p) and birth height was 50 cm (50-75 p), respectively. Her parents were third-degree relatives. Her father's and mother's heights were 165 cm (-1.65 SDS), and 135.9 cm (-4.2 SDS), respectively. She had healthy four siblings. Her physical examination at presentation showed a short stature, obesity, round face, low nasal bridge, and shortened metacarpals (picture 1 and 2). Her pubertal stage was in tanner phase 1. She was evaluated as mentally retarded in a mild degree.

Skeletal maturation assessment by direct hand wrist radiography revealed shortened metacarpals and metatarsals (picture 3) and her bone age was consistent with her age. Her thyroid ultrasonography and cranial magnetic resonance imaging were both reported as normal. Hypothyroidism and elevated PTH levels with normocalcemia and normal 25-OH vitamin D levels were detected in her laboratory tests. Laboratory findings including complete blood counts, biochemical parameters, TSH, free T4, calcium, phosphorus, alkaline phosphatase, PTH level, 25-hydroxyvitamin D, insulin like growth factor 1 (IGF-1) were given in Table 1.

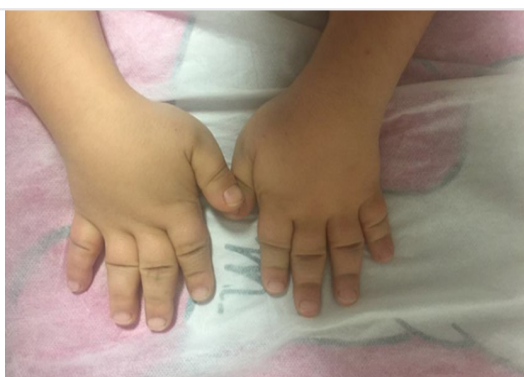


Figure 1. Brachydactyly

As a result of clinic and laboratory tests, the findings were consistent with PHP type Ia with hypothyroidism and normocalcemia, her GNAS gene sequencing analysis was performed; C-308T>C (p1103T) transformation was detected, which was previously reported in PHP type Ia patient. Oral L-thyroxine treatment was initiated to the patient. Her growth velocity and calcium and phosphorus levels are still on follow-up.

Written informed consent was obtained from the patient's parents for publication of this case report.

Discussion

Pseudohypoparathyroidism Ia is the most prevalent PHP type. Along with typical phenotypic findings, cases showing heterogeneity have also been reported (12-14). Our patient had typical AHO phenotypes.

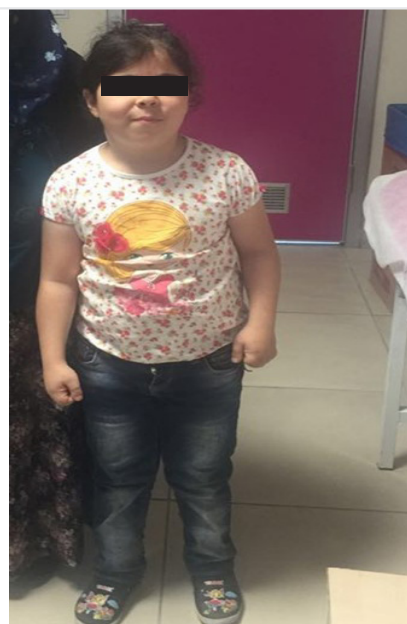

Figure 2. Short stature, round face, obesity

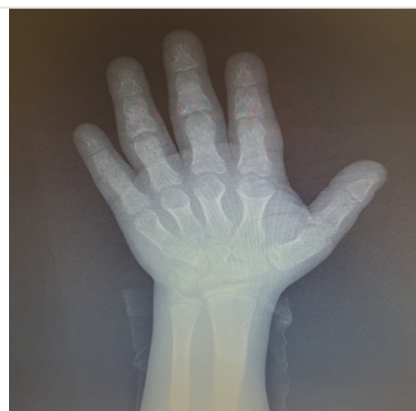

Figure 3. Hand and wrist radiograph with diagnosis of brachydactyly and bone dysplasia

Table 1.

Hemoglobin (g/dL)*	12.9 (11-13)**	ALT (U/L)	15 (8.7-39)
MCV (fL)	85.6 (75-90)	AST (U/L)	192 (100-500)
Platelet (10*3 u/L)	227 (142-424)	FT4 (pmol/L)	8.71 (11.2-18.6)
Leucocyte (10*3 u/L)	7.2 (6-17)	TSH (mIU/L)	9.2 (0.51-4.82)
Sodium (mmol/L)	140 (139-146)	Calcium (mg/dL)	9.7 (8.8-10.8)
Potassium (mmol/L)	4.4 (4.1-5.3)	Phosphorus (mg/dL)	5.8 (3.78-6.19)
Chlorine (mmol/L)	105 (98-106)	ALP (U/L)	205 (135-537)
BUN (mg/dL)	12.5 (5.1-16.8)	PTH (pg/mL)	436.9 (15-68.3)
Creatine (mg/dL)	0.44 (0.35-0.59)	25 OH vit D (ng/mL)	28 (20-70)
Fasting Glucose (mg/dL)	80 (50-80)	IGF-1 (ng/mL)	197 (51-303)

MCV: mean cell volume, BUN: blood urea nitrogen, AST: aspartate aminotransferase, ALT: alanine aminotransferase, FT4: free tetraiodothyronine, TSH: thyroid stimulating hormone, ALP: alkaline phosphatase, IGF-1: insulin like growth factor-1, *Laboratory measurement units; **Reference Values

Transport system which is sensitive to parathormone consists of three sections namely receptor, adenyl cyclase and protein G. The *GNAS* gene encodes the alpha-stimulatory subunit (Gs) of the intracellular G protein, which stimulates the production of cAMP under certain physiologic conditions (7). Gs alpha protein activity in PHP-Ia is low as a result of *GNAS* 1 gene mutation therefore, sufficient c-AMP response to PTH cannot occur in receptor level (15-18). Resistance to other hormones which uses protein G as a second messenger, may also be observed. Moreover, the most common resistance is observed against TSH, which affects more than 90% of PHP patients type Ia (19,20). Previous reports have shown hypothyroidism may be the first manifestation of PHP type Ia in absence of hypocalcemia and elevated PTH levels (8-21). In our case, hypothyroidism with elevated TSH and decreased sT4 levels was detected.

The characteristic findings of the disorder are hypocalcemia, hyperphosphatemia and high level of PTH. However, previously normocalcemic cases have also been reported (10,22-24). Tamada et al. (24) reported a case with R358H mutation with normocalcemia. We have detected C-308T >C (p1103T) change in our case. The mechanism behind the fact of normocalcemia cannot be explained completely. It is proposed that normal serum calcium concentrations in these patients may be explained by the presence of normal bone responsiveness to PTH (10,25,26). Further studies are needed on this issue.

In conclusion, we have presented a PHP type Ia patient with normocalcemia and hypothyroidism caused by C-308T >C (p1103T) change in the *GNAS* gene. In children with hypothyroidism without apparent etiology, *GNAS* 1 gene mutations should be also considered even calcium levels are normal.

Ethics

Informed Consent: Written informed consent was obtained from the patient's parents for publication of this case report.

Peer Review: Internally peer-reviewed.

Authorship Contributions

Concept: E.K., İ.T.Ö., G.Y., Design: E.K., İ.T.Ö., Y.C., Data Collection or Processing: E.K., İ.T.Ö., G.Y., Analysis or Interpretation: İ.T.Ö., Y.C., G.Y., Literature Search: E.K., G.Y., İ.T.Ö., Writing: E.K., İ.T.Ö.

Conflict of Interest: No conflict of interest was declared by the authors.

Financial Disclosure: The authors declared that this study received no financial support.

References

- Albright F, Burnett CH, Smith PH, Parson W. Pseudo-hypoparathyroidism--an example of 'Seabright-Bantam syndrome': report of three cases. *Endocrinology* 1942;30:922-32.
- Bastepe M, Jüppner H. *GNAS* locus and pseudohypoparathyroidism. *Horm Res* 2005;63:5.
- Spiegel AM, Weinstein LS, Shenker A. Abnormalities in G protein-coupled signal transduction pathways in human disease. *J Clin Invest* 1993;92:1119.
- Ahmed SF, Dixon PH, Bonthron DT, Stirling HF, Barr DG, Kelnar CJ, et al. *GNAS*1 mutational analysis in pseudohypoparathyroidism. *Clin Endocrinol (Oxf)* 1998;49:525-31.
- Nakamoto JM, Sandstrom AT, Brickman AS, Christenson RA, Van Dop C. Pseudohypoparathyroidism type Ia from maternal but not paternal transmission of a Gsalpha gene mutation. *Am J Med Genet* 1998;77:261-7.
- Levine MA, Downs RW Jr, Moses AM, Breslau NA, Marx SJ, Lasker RD, et al. Resistance to multiple hormones in patients with pseudohypoparathyroidism. Association with deficient activity of guanine nucleotide regulatory protein. *Am J Med* 1983;74:545-56.
- Carlson HE, Brickman AS. Blunted plasma cyclic adenosine monophosphate response to isoproterenol in pseudohypoparathyroidism. *J Clin Endocrinol Metab* 1983;56:1323-6.
- Mantovani G, Spada A. Mutations in the Gs alpha gene causing hormone resistance. *Best Pract. Res. Clin. Endocr. Metab* 2006;20:501-13.

9. Downs RW Jr, Levine MA, Drezner MK, Burch WM Jr, Spiegel AM. Deficient adenylate cyclase regulatory protein in renal membranes from a patient with pseudohypoparathyroidism. *J Clin Invest* 1983;71:231-5.
10. Levine MA, Jap TS, Hung W. Infantile hypothyroidism in two sibs: an unusual presentation of pseudohypoparathyroidism type Ia. *J Pediatr* 1985;107:919-22.
11. Mantovani G1, Maghnie M, Weber G, De Menis E, Brunelli V, Cappa M, et al. Growth hormone-releasing hormone resistance in pseudohypoparathyroidism type Ia: new evidence for imprinting of the Gs-alpha gene. *J Clin Endocrinol Metab* 2003;88:4070-4.
12. de Nancrales GP, Fernández-Rebollo E, Santin I, García-Cuartero B, Gaztambide S, Menéndez E, et al. Epigenetic defects of GNAS in patients with pseudohypoparathyroidism and mild features of Albright's hereditary osteodystrophy. *J Clin Endocrinol Metab* 2007;92:2370-3.
13. Stirling HF, Barr DG, Kelnar CJ. Familial growth hormone releasing factor deficiency in pseudopseudohypoparathyroidism. *Arch Dis Child* 1991;66:533-5.
14. Breslau NA, Notman DD, Canterbury JM, Moses AM. Studies on the attainment of normocalcemia in patients with pseudohypoparathyroidism. *Am J Med* 1980;68:856-60.
15. Ish-Shalom S, Rao LG, Levine MA, Fraser D, Kooh SW, Josse RG, et al. Normal parathyroid hormone responsiveness of bone-derived cells from a patient with pseudohypoparathyroidism. *J Bone Miner Res* 1996;11:8-14.
16. Hewitt M, Chambers TL. Early presentation of pseudohypoparathyroidism. *J Roy Soc Med* 1988;81:666-7.
17. Izraeli S, Metzker A, Horev G, Karmi D, Merlob P, Farfel Z. Albright hereditary osteodystrophy with hypothyroidism, normocalcemia, and normal Gs protein activity: a family presenting with congenital osteoma cutis. *Am J Med Genet* 1992;43:764-7.
18. Zung A, Herzenberg JE, Chalew SA. Radiological case of the month. *Arch Pediatr Adolesc Med* 1996;150:643-4.
19. Germain-Lee EL, Groman J, Crane JL, Jan deBeur SM, Levine MA. Growth hormone deficiency in pseudohypoparathyroidism type Ia: another manifestation of multihormone resistance. *J Clin Endocrinol Metab* 2003;88:4059-69.
20. Mantovani G, Bondioni S, Linglart A, Maghnie M, Cisternino M, Corbetta S, et al. Genetic analysis and evaluation of resistance to thyrotropin and growth hormone-releasing hormone in pseudohypoparathyroidism type Ib. *J Clin Endocrinol Metab* 2007;92:3738-42.
21. Weisman Y, Golander A, Spier Z, Farfel Z. Pseudohypoparathyroidism type Ia presenting as congenital hypothyroidism. *J Pediatr* 1985;107:413-5.
22. Ozbey N. Pseudohypoparathyroidism with normocalcemia. *J Endocrinol Invest* 2001;24:642-3.
23. Thiele S, Werner R, Ahrens W, Hoppe U, Marschke C, Staedt P, et al. A disruptive mutation in exon 3 of the GNAS gene with Albright hereditary osteodystrophy, normocalcemic pseudohypoparathyroidism, and selective long transcript variant Gsalpha-L deficiency. *J Clin Endocrinol Metab* 2007;92:1764-8.
24. Tamada Y, Kanda S, Suzuki H, Tajima T, Nishiyama T. A Pseudohypoparathyroidism Type Ia Patient with Normocalcemia. *Endocrine Journal* 2008;55:169-73.
25. Zerwekh JE, Breslau NA. Human placental production of 1 alpha,25-dihydroxyvitamin D3: biochemical characterization and production in normal subjects and patients with pseudohypoparathyroidism. *J Clin Endocrinol Metab* 1986;62:192-6.
26. Murray TM, Rao LG, Wong MM, Waddell JP, McBroom R, Tam CS, et al. Pseudohypoparathyroidism with osteitis fibrosa cystica: direct demonstration of skeletal responsiveness to parathyroid hormone in cells cultured from bone. *J Bone Miner Res* 1993;8:83-91.